

### **How do riders affect their horse's back?**

As a rider, it is important to understand what anatomical structures of the horse you sit on and how they move underneath you.

There are 2 types of tissue involved: rigid and elastic. The rider directs the horse's movement through the elastic tissues, (muscles, tendons and ligaments) to the rigid tissues (bones of the skeleton) to move the horse's body from place to place. For this musculoskeletal system to remain intact, the energy produced by the muscles must be distributed correctly.

The horse's back is responsible for transmitting propulsive forces forwards from the hind legs and supporting the rider's weight. The strength of the back comes from the vertebra, spinal ligaments, tendons and muscles. This keeps the thoracolumbar spine relatively rigid and, with the ventral longitudinal ligament, supports the rider's weight. The deep muscles of the back help to maintain posture.

There are a group of muscles known as the 'ventral muscle chain', (see red in Figure 1). When these are used, the vertebral bodies of the spine form a slight convex arc allowing the horse to use its back. The ventral chain includes the abdominal muscles that lift and support the back and also maintain pelvic tilt. When a horse has weak abdominal muscles then the natural curvature of the spine sags and the horse appears to have large hanging abdomen.

For the horse to now move forward with its back lifted, the thoracic sling (in green on Figure 1) of the forehand, including the pectoral and serrated muscles, must be utilised. This is where the forelegs attach to the rib cage through the base of the neck. In the ridden horse, the elasticity of this area directly correlates to the energy of the forward stride. If the serrated muscles are bruised by the pressure of girth straps or the neck is fixed by the rider's hands the whole system fails. Instead of free flowing movement, the horse's chest cavity is jerked with every stride so movement appears restricted.

An important sub lumbar muscle of the hind leg is the iliopsoas (in blue on Figure 1). This supports the lumbosacral joint and with the abdominal muscles helps maintain the correct angle of the pelvis. If the thoracolumbar region is extended (i.e. the back is 'hollow') then the lumbosacral region is also extended. The pelvis is then at a more obtuse angle so engagement of the hind legs is more difficult. The iliopsoas also braces the spine when the hind limb muscles push the horse forwards. If, when ridden, this muscle does not soften the horse will not engage his hindquarters correctly. The structures of the thoracolumbar region and stifle then bear the brunt of the power produced by the hind limb muscles. They can then become damaged in the process.

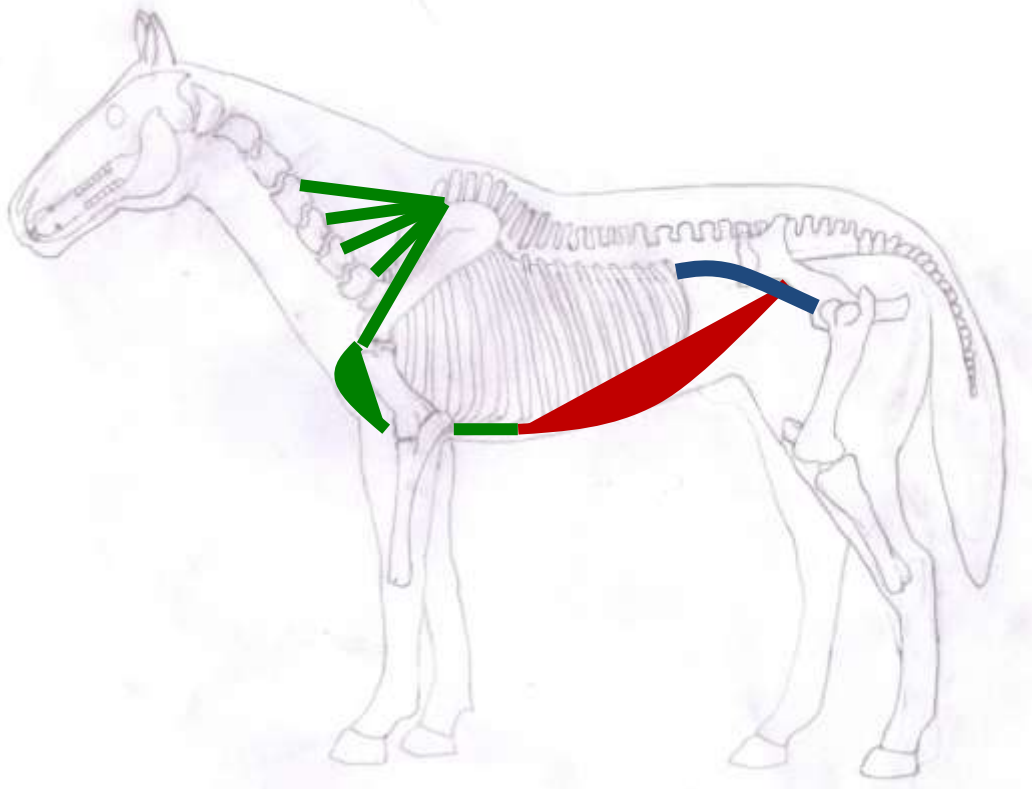


Figure 1: Sketch of Horse's Skeleton with Ventral Muscle Chain in Red, Thoracic Sling in Green and the Sub Lumbar Muscles in Blue.

The ventral chain, thoracic sling and sub lumbar muscles make up the horse's core group of muscles. Correct use, strength, and stability of these can improve balance, posture and performance of the horse, and its weight bearing capacity of the rider.

In the head and neck there are continuous muscular and ligamentary structures from the poll through to the thoracic sling. The position of the head and neck affects the back and so can be used to the rider's advantage. For example, in a young horse the rider can skilfully position the head and neck whilst engaging the hind leg thereby supporting the horses back whilst it strengthens, (see Figure 2).



Figure 2: Young Horse being ridden with correct head and neck position. Note: the rider is slightly leaning forward to encourage the horse's back to lift using the horse's core group of muscles. When the horse is stronger and in better balance the rider can then sit more upright in a correct position. Notice the angle of the pelvis as the hind legs are engaged.

However, in a tense high head and neck position, the core muscle group are inhibited so engagement and correct back posture is lost, (see Figure 3).



Figure 3: the same horse in a moment of resistance. The head and neck are very high, the ventral chain has slackened and the sub lumbar muscles have changed the angle of the pelvis so the hind quarters are disengaged.

In order to keep these muscles supple and strong there are exercises that can be performed on the horse and on the ground. These vary from pole work and correct lunging to performing carrot stretches and using reflex points. If there is an issue doing one or all of these exercises then professional help should be sought.

Claire Warman – Equine & Small Animal Sports Therapist [www.clairewarman.co.uk](http://www.clairewarman.co.uk) 07799883635

Artwork author's own

Photography by Andrew Watts